

Response to a letter to the editor

Endoscopic Diagnosis of Hookworms

Gabriel Mosquera-Klinger, MD.¹

Keywords

Hookworm infections, *Trichuris trichiura*, antiparasitic agents, gastrointestinal endoscopy.

1. Gastroenterology and Digestive Endoscopy Unit of the Hospital Pablo Tobón Uribe; Medellín, Colombia.

*Correspondence: Gabriel Mosquera-Klinger, MD, gami8203@yahoo.com

Received: 17/04/20
Accepted: 25/04/20

To start, I would like to express my appreciation for the interest shown in the clinical case and in endoscopic diagnosis of hookworms. (1) I consider the contribution and the deep academic discussion based on endoscopic semiology of differential diagnosis of intestinal parasitosis raised in the letter to the editor to be of great relevance.

I agree that the primary location or habitat of hookworms is the upper digestive tract, especially the small intestine (duodenum and jejunum). Nevertheless, there have been increasing numbers of reported cases in which hookworms are found in the colorectal region and even in the cecal appendix. (2-5)

Trichuris trichiura is an intestinal parasite whose usual habitat is the colon and which is most frequently diagnosed through colonoscopy. It constitutes a differential diagnosis that must be considered in this case. But it is essential to note that *Trichuris trichiura* gets its name from the Greek word *Thrikhos*, which means hair, given the thin shape of the anterior two thirds of this parasite.

This gives it its typical whip-like appearance of a long, thin anterior whip lash with a thick posterior whip handle. The female's posterior end is straight while the male has a pronounced curvature and has a copulatory spicule that is 3 to 5 cm long. (6)

Morphologically, hookworms have been described as white cylindrical parasites that measure 10 to 15 mm in length. Their anterior ends are generally straight, but their bodies are curved: wide C-shaped curves for *Ancylostoma duodenale* but slight S curves in the opposite direction for *Necator americanus*. These findings are very similar to those seen in **Figure 1** of the case under discussion.

Given the morphological differences just described, we concluded that even though a male *T. trichiura* has a pronounced curvature that gives it a "coiled" appearance, its most characteristic feature is its front end whip (**Figure 2**) which was not evident in our case. (7)

Two other clinical data make it unlikely that the parasites observed through colonoscopy in this case were *T. trichiura*.

The first is that *T. trichiura* is not hematophagous. The mechanisms associated with anemia in this type of parasitosis are related to mechanical damage of the mucosa by insertion of the anterior portion of the parasite into the mucosa. This trauma generates local inflammatory changes and hemorrhaging which is why patients frequently have symptoms such as diarrhea, bleeding, and dysentery. There are even presentations that are indistinguishable from inflammatory bowel disease although not in our case. (8, 9) The severity of the inflammation is clearly related to the quantity of parasites.

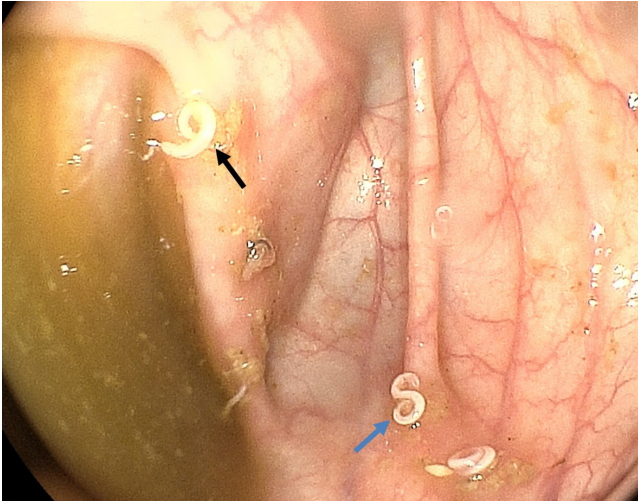


Figure 1. Multiple hookworms in the right colon. The blue arrow shows the characteristic S-shape of *N. americanus*, while the black arrow indicates the characteristic C-shape of *A. duodenale*.

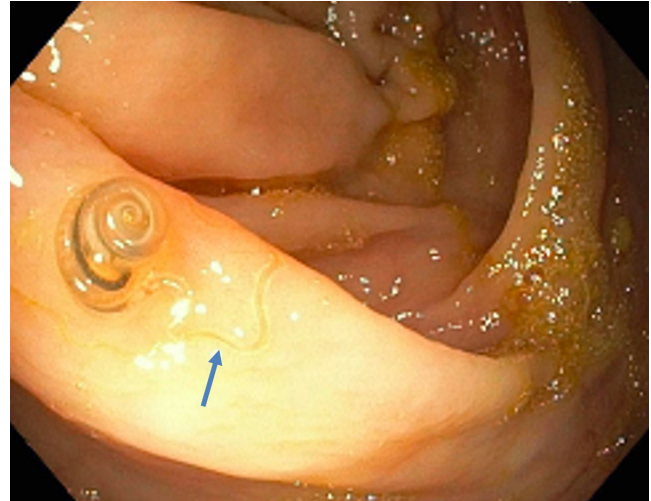


Figure 2. The blue arrow shows the characteristic anterior whip of the parasite. Taken from reference 7.

The second was our patient's very good clinical response to treatment with pyrantel pamoate. (1) Pyrantel pamoate and benzimidazoles are the drugs of choice for hookworms. Recommended treatment calls for three-day schedules every six months for three years. Thus, pyrantel pamoate has high cure and egg reduction rates for hookworms, but it should not be used for *T. trichiura* because of its ineffectiveness. (1, 6)

Within this context, benzimidazoles have historically been recommended as the treatment of choice for *T. trichiura* despite the fact that cures occur in less than 75% of cases with monotherapy. (6) Egg eradication rates can be improved by combined benzimidazole and ivermectin regimens as shown in a study by Knopp et al. (10)

In that study, significant eradication rates as high as 97% were achieved with the combination of mebendazole and ivermectin while an eradication rate of 91% was achieved with albendazole and ivermectin. (10) Nevertheless, when ivermectin is used alone to treat these parasites, its cure rate is only 11%, and egg its reduction rate is only 59%. (6, 11)

Consequently, it is not recommended as monotherapy for either *T. trichiura* or for hookworms.

We agree that in Colombia, polyparasitism frequently occurs in individuals from rural areas. We also consider doubts about the types of parasites found in endoscopic studies to be pertinent because they increase the probability of establishing an accurate diagnosis when parasites are extracted.

With the exceptions of malaria, leishmaniasis, and lymphatic filariasis, the global disease burden of hookworms (measured in disability-adjusted life years) outweighs all other major tropical infectious diseases. (4)

For this reason, it seems fundamental to me to clarify that hookworms are the helminths that are most closely associated with severe chronic anemia. In all cases they must be treated with effective antiparasitic agents for at least 3 years, as established in this patient. In contrast, although severe *T. trichiura* infections should always be treated, mild *T. trichiura* infections without clinical manifestations have been described. In these cases, treatment is not strictly required. (6)

REFERENCES

1. Pizza-Restrepo J, Mosquera-Klinger G. Diagnóstico endoscópico de uncinaria: presentación de un caso con anemia ferropénica grave. *Rev Colomb Gastroenterol.* 2019;34(4):433-437. <http://doi.org/10.22516/25007440.289>
2. Thomas V, Harish K, Tony J, Sunilkumar R, Ramachandran TM, Anitha PM. Colitis due to *Ancylostoma duodenale*. *Indian J Gastroenterol.* 2006;25(4):210-211.
3. Wang CH, Lee SC, Huang SS, Chang LC. Hookworm infection in a healthy adult that manifested as severe eosinophilia and diarrhea. *J Microbiol Immunol Infect.*

- 2011;44(6):484-487.
<http://doi.org/10.1016/j.jmii.2011.04.010>
4. Hotez PJ, Bethony J, Bottazzi ME, Brooker S, Buss P. Hookworm: “the great infection of mankind”. *PLoS Med*. 2005;2(3):e67.
<http://doi.org/10.1371/journal.pmed.0020067>
 5. Changela K, Sharma S, Reddy M. Ancylostoma duodenale: Lost Its way into Appendix. *Am J Gastroenterol*. 2017;112(suppl 1):S776-S778.
<https://doi.org/10.14309/0000434-201710001-01429>
 6. Botero D, Restrepo M. Parasitosis intestinales por nematodos. En: Botero D, Restrepo M. *Parasitosis humanas*. Medellín: Corporación para Investigaciones Biológicas; 1999. p. 139-60.
 7. Sunkara T, Sharma SR, Ofosu A. Trichuris trichiura-An Unwelcome Surprise during Colonoscopy. *Am J Trop Med Hyg*. 2018;99(3):555-556.
<http://doi.org/10.4269/ajtmh.18-0209>
 8. Ok KS, Kim YS, Song JH, Lee JH, Ryu SH, Lee JH, Moon JS, Whang DH, Lee HK. Trichuris trichiura infection diagnosed by colonoscopy: case reports and review of literature. *Korean J Parasitol*. 2009;47(3):275-280.
<http://doi.org/10.3347/kjp.2009.47.3.275>
 9. Jha AK, Goenka MK, Suchismita A. Clinical correlates of trichuriasis diagnosed at colonoscopy. *Indian J Gastroenterol*. 2017;36(5):420-423.
<http://doi.org/10.1007/s12664-017-0795-8>
 10. Knopp S, Mohammed KA, Speich B, Hattendorf J, Khamis IS, Khamis AN, Stothard JR, Rollinson D, Marti H, Utzinger J. Albendazole and mebendazole administered alone or in combination with ivermectin against Trichuris trichiura: a randomized controlled trial. *Clin Infect Dis*. 2010;51(12):1420-1428.
<http://doi.org/10.1086/657310>
 11. Marti H, Haji HJ, Savioli L, Chwaya HM, Mgeni AF, Ameir JS, Hatz C. A comparative trial of a single-dose ivermectin versus three days of albendazole for treatment of Strongyloides stercoralis and other soil-transmitted helminth infections in children. *Am J Trop Med Hyg*. 1996;55(5):477-481.
<http://doi.org/10.4269/ajtmh.1996.55.477>